

LAPAROSCOPIC-ASSISTED RADICAL CYSTECTOMY WITH U-SHAPED ORTHOTOPIC ILEAL NEOBLADDER CONSTRUCTED USING NONABSORBABLE TITANIUM STAPLES

SIDNEY C. ABREU, MARDHEN B. ARAÚJO, RÔMULO A. SILVEIRA, ROMMEL P. REGADAS, DANILO G. PINHEIRO, FREDERICO I. MESSIAS, RENATO S. ARGOLLO, GLAUCO A. GUEDES, JOÃO BATISTA C. GADELHA, AND GILVAN N. FONSECA

ABSTRACT

Introduction. Recently, nonabsorbable staples have been safely used in a variety of urologic open and laparoscopic extirpative and reconstructive procedures. We report the surgical steps of our technique of U-shaped orthotopic ileal neobladder created with titanium staples.

Technical Considerations. Using stay stitches, a 45 to 50-cm ileal segment is arranged in a U shape with two segments of approximately 20 cm and an afferent limb of 5 or 10 cm. An opening is made at the lowest point of the U-ileal segment on its antimesenteric border. The jaws of the 80 × 3.5-mm nonabsorbable mechanical stapler are accommodated within the bowel loop and fired twice, bringing together and detubularizing approximately 15 cm of each arm of the U. To complete the pouch detubularization, another small opening is made at the bottom of the chimney on its medial border. After this, a third nonabsorbable mechanical stapler had its jaws introduced through this opening and through the open end of the bowel segment on the right side and the stapler is fired, completing the U pouch. Subsequently, the open ends of the U segment and the opening made at the base of the afferent limb are closed with absorbable running sutures.

Conclusions. Our technique is feasible and may represent an alternative to expand the spectrum of continent urinary reservoirs that could be expeditiously created with nonabsorbable staples. Continued surveillance is mandatory to determine the lithiasis-inducing potential of these titanium staples within the urinary tract. *UROLOGY* 68: 193–197, 2006. © 2006 Elsevier Inc.

In the past decade, absorbable polyglycolic acid staples were used in an attempt to simplify the operative procedure and reduce the overall surgical time required to construct an orthotopic urinary reservoir after open radical cystectomy.^{1,2} Although the use of such absorbable staples significantly decreased the operative time, its widespread use was restricted because of problems related to reservoir malfunction, in particular during the construction of the W-configured ileal reser-

voir, and the greater costs of such staples, which offset the costs savings realized by the reduced operative time.^{1,2}

Recently, nonabsorbable titanium staples have been used in a variety of urologic open and laparoscopic extirpative and reconstructive procedures, including bladder cuff resection during laparoscopic nephroureterectomy, laparoscopic pelvioplasty, and open and laparoscopic neobladder construction.^{3–9} Because of its corrosive resistant nature and low toxicity, titanium seems to be well tolerated inside the urinary tract, and thus has been safely used during the construction of urinary reservoirs. Moreover, because the bowel mucosa apparently rapidly covers most of, if not the entire, staple lines within the reservoir, as observed during cystoscopy at the second postoperative month,⁸ stone formation occurs at an acceptable rate of up to 6%

From the Andros Hospital Urológico de Brasília, Brasília, Brazil; Section of Urology, Federal University of Ceará, Ceará, Brazil; and Section of Urology, Federal University of Goiás, Goiás, Brazil

Reprint requests: Sidney C. Abreu, M.D., Hospital Urológico de Brasília, SEP Sul, Q. 714/914, Ed. Sta. Maria, térreo, Brasília, DF 70670109 Brazil. E-mail: sidneyabreu@hotmail.com

Submitted: October 13, 2005, accepted (with revisions): February 6, 2006

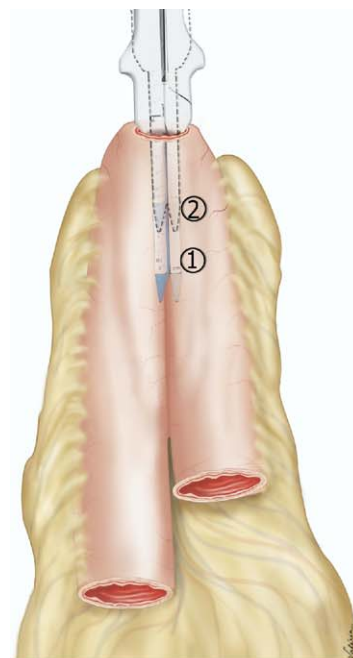
(mean follow-up 20 months, range 8 to 47).⁹ Finally, titanium staples are cheaper than the absorbable ones and are also available for laparoscopic intracorporeal procedures (EndoGIA stapler, U.S. Surgical, Norfolk, Conn).

Encouraged by the pioneer work of Fontana and colleagues,⁹ who reported the open surgical construction of a Y-shaped ileal neobladder with nonabsorbable titanium staples, we have successfully replicated their technique using a laparoscopic-assisted and pure laparoscopic approach.^{7,8} However, in an attempt to duplicate what we had performed in the open procedure, we decided to create a laparoscopic-assisted constructed U-shaped ileal neobladder using titanium staples. We report the surgical steps of our technique, broadening the spectrum of continent urinary reservoirs that can be created with nonabsorbable staples in laparoscopic or open procedures.

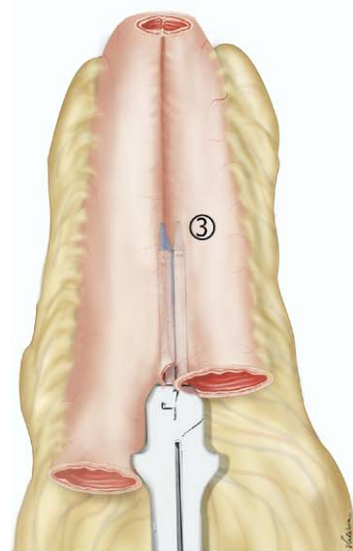
TECHNICAL CONSIDERATIONS

Starting in September 2004, we performed 11 laparoscopic radical cystectomy and urinary diversion procedures. Three patients diagnosed with muscle-invasive bladder cancer with negative metastatic findings consented to undergo laparoscopic radical cystoprostatectomy with a U-shaped continent urinary reservoir constructed with nonabsorbable titanium staples.

Laparoscopic radical cystoprostatectomy with bilateral pelvic lymphadenectomy was performed through a standard five-port transperitoneal approach, as described in detail previously.¹⁰⁻¹³ After the extirpative portion of the operation, the entrapped specimen was removed intact within a Lapsac through a 5-cm muscle-splitting Pfannenstiel or midline incision. Subsequently, the distal ileum was identified and brought outside the abdominal cavity through the extraction incision. A 45 to 50-cm ileal segment was isolated 15 to 20 cm proximal to the ileocecal valve, and a side-to-side enteral-enteral anastomosis was performed to reestablish bowel continuity using conventional open surgical techniques. Using absorbable stay stitches, the isolated intestinal segment was then arranged in a U shape with two segments of approximately 20 cm and an afferent limb (left side) of 5 or 10 cm. An opening was then made at the lowest point of the U-ileal segment on its antimesenteric border. The jaws of the 80 × 3.5-mm nonabsorbable mechanical stapler (Multifire GIA, U.S. Surgical) were accommodated within the bowel loop and fired twice, bringing together and detubularizing approximately 15 cm of each arm of the U (Fig. 1A). To complete the pouch detubularization, another small opening was made at the bottom of the chimney (afferent limb on the left side)



A



B

FIGURE 1. (A,B) Schematic showing U-shaped neobladder being rapidly created with three sequential firings of mechanical stapler.

on its medial border. Next, the jaws of a third nonabsorbable mechanical stapler were introduced through this opening and through the open end of the bowel segment on the right side (Fig. 1B). The stapler was fired, completing the U pouch. During stapling, care was taken to properly position the active cutting surfaces of the stapler device at the antimesenteric border to ensure the bowel vascular supply was not jeopardized (Fig. 2). The index finger or the laparoscope (Fig. 3) was then introduced within the recently fashioned pouch to ensure that the staple rows reached each other and had not created an undesirable septation within the pouch by

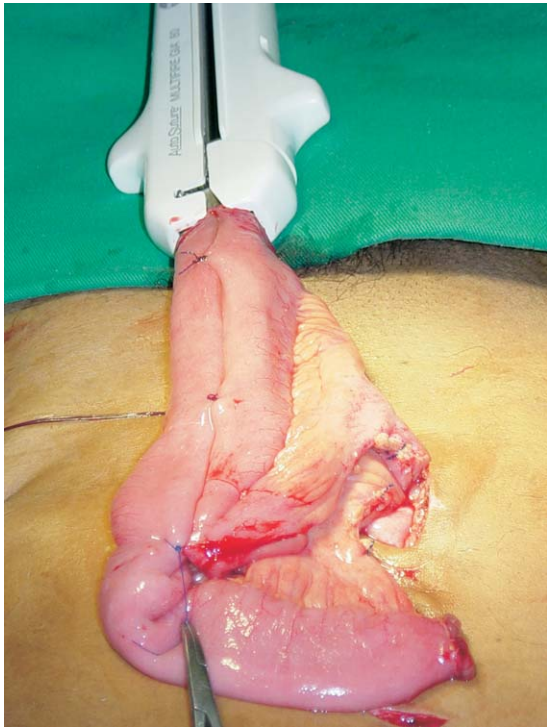


FIGURE 2. Isolated 50-cm ileal segment brought outside abdominal cavity through 5-cm midline incision and configured into U-shape with aid of stay stitches. Subsequently, an 80 × 3.5-mm stapler device was used to expeditiously create central part of neobladder.

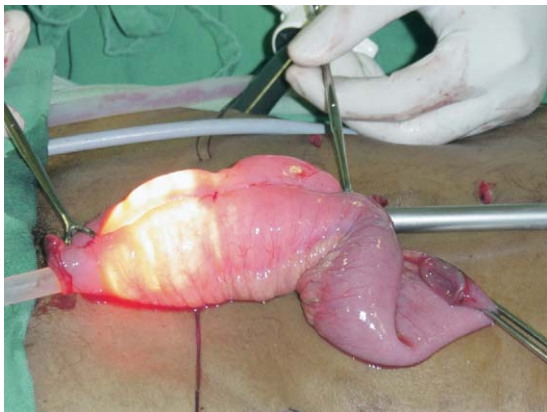


FIGURE 3. Recently fashioned neobladder distended with carbon dioxide and laparoscope introduced within reservoir to check for presence of septations.

the lack of complete anastomoses between the adjacent limbs. Subsequently, the open ends of the U segment and the opening made at the base of the afferent limb were closed with absorbable running sutures. With the aid of the laparoscope, the ureters, which were previously anchored to the anterior abdominal wall with stay stitches, were identified and brought outside the abdominal cavity. Laparoscopic visualization ensured that the ureters were not twisted or rotated. Alternatively, two 100 × 3.5 mm SGIA staples (DST Series, U.S. Sur-

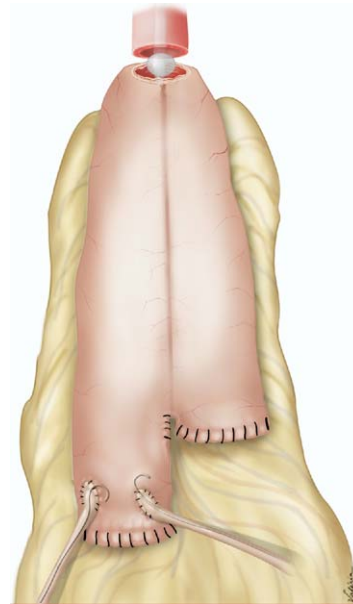


FIGURE 4. Schematic showing final aspect of U-shaped neobladder after ureters have been reimplanted to afferent limb.

gical) could be used, one fired from cephalad to caudad and the other from caudad to cephalad. This, at least theoretically, would avoid the staple line crossing that would result in staple clusters and a potential nidus for encrustation and stone formation. Subsequently, the ureters were freshened and spatulated for approximately 1.5 cm. Bilateral (6F) double-J ureteral stents were then inserted up to the renal pelvis, and the ureters were directly anastomosed to the openings made at the neobladder's afferent limb using running 4-0 Vicryl sutures (Fig. 4). The recently created neobladder was reinserted inside the abdominal cavity, and the 5-cm extraction incision was closed. The pneumoperitoneum was re-established and the U-neobladder was anastomosed to the urethra with four to six interrupted 2-0 Monocryl sutures, over a 22F Foley catheter, using intracorporeal laparoscopic free-hand suturing. Finally, the neobladder limb was secured to the retroperitoneum with a stay stitch, and a suction drain was left in the deep pelvis.

RESULTS

The demographic, intraoperative, and postoperative data are presented in Table I.

COMMENT

Titanium staples have been safely used in urology for more than a decade.³⁻⁸ In line with this concept, Fontana *et al.*⁹ have recently reported their technique of Y-shaped ileal neobladder creation, which was described as an “easy, fast, and

TABLE I. Demographic and Intraoperative and postoperative data

| Variable | Patient 1 | Patient 2 | Patient 3 |
|---|------------------|-----------|-----------------|
| Age (yr) | 64 | 62 | 58 |
| Total OR time (hr) | 6.0 | 6.5 | 6.0 |
| Time for bowel work and neobladder construction (min) | 45 | 40 | 35 |
| Intraoperative blood loss (mL) | 350 | 100 | 550 |
| Blood transfusion (U) | — | — | 1 |
| Intraoperative complications | — | — | — |
| Postoperative complications | Urinary fistula* | — | Paralytic ileus |
| Stone formation on cystoscopy (2 mo postoperatively) [†] | No | No | No |

KEY: OR = operative time.

* Patient did not follow recommendations to properly empty neobladder, resulting in significant postvoid urinary volume and in cutaneous urinary fistula formation; this fistula was managed conservatively and healed spontaneously with 14 days of indwelling catheterization.

[†] During cystoscopy, we also observed that most of the staple lines were covered by intestinal mucosa, except for two 0.5–1.0-cm spots at which we could see staples clusters.

reliable” procedure. Using a mechanical stapler, they were able to expeditiously create an ileal neobladder within approximately 20 minutes. Concerns related to the use of nonabsorbable staples within the urinary diversion were overcome by an acceptable 6% rate of stone formation at the staple line⁹ comparable to the 5% to 12.9% incidence of stone formation within conventionally constructed reservoirs.^{14,15} Also, the stones that would eventually be formed at titanium staples line could be easily managed endoscopically and recognized early by ultrasound examination.⁹ Even when the staples are visible within the urinary tract, they do not necessarily induced encrustation or stone formation.^{4–6} Nevertheless, the risk of stone formation at exposed staple sites should not be underestimated. Perhaps a preoperative metabolic evaluation should be performed to identify those patients at greater risk of stone disease to exclude these patients from the option of receiving a urinary diversion constructed with titanium staples.^{15,16} Moreover, because titanium staples have excellent tissue and fluid biocompatibility and are not as bulky as the absorbable one, it is less likely that they could cause inflammatory reactions and bowel ischemia, leading to extensive fibrosis surrounding the reservoir that might preclude it from gaining adequate capacity.^{1,2} Furthermore, the use of nonabsorbable staples has the clear advantage of decreased costs with disposable material, because titanium staples are considerably cheaper than the absorbable ones.

Although the Y-neobladder of Fontana *et al.*⁹ did not result in any statistically significant urodynamic differences compared with the other more commonly used neobladders, it did lead to a smaller capacity, slower return to continence, and greater day and nighttime voiding frequencies. These conclusions have been illustrated by a mean maximal functional bladder capacity of 180 mL at 3 months, 220 mL at 6 months, 280 mL at 12 months, and 390 mL at 24 months postoperatively, a mean daytime voiding frequency of 8 micturi-

tions at 3 months, 6 at 6 months, and 5 micturitions at 12 and 24 months, and a mean nighttime voiding frequency of 4 micturitions at 3 months, 3 at 6 months, and 2.5 and 2.3 micturitions at 12 and 24 months, respectively.⁹

In an attempt to reduce these problems, we constructed a U-shaped ileal neobladder using titanium staples, duplicating the established open surgical principals of a continent urinary reservoir with a large volume and low pressure.¹⁷ Therefore, compared with the Y-neobladder, the U-shaped neobladder has a longer detubularized central segment, 20 cm versus 14 cm for the Y-neobladder, providing a larger volume capacity owing to the bigger radius achieved and a lower internal pressure owing to less coordinated peristaltic wall contractions.¹⁴ Even though we have limited follow-up information, it is likely that the satisfactory quality of life provided by the conventional U-shaped ileal neobladder will also be observed with our stapled U-neobladder. This has been suggested by our preliminary data at 3 months of daytime continence achieved in all patients, nighttime voiding frequency of two to four micturitions, and a mean maximal functional bladder capacity of 322 mL.

CONCLUSIONS

Our technique of laparoscopic assisted U-shaped ileal neobladder is feasible and may represent an alternative to expand the spectrum of continent urinary reservoirs that could be created with nonabsorbable staples. Although the use of titanium staples may be seen by critics as a “short cut” to the use of conventional suturing techniques, we do not view this as a negative perspective. We believe this technique is rather a “smart cut” and may become widely used during laparoscopic and open procedures to expeditiously and safely create an orthotopic urinary reservoir. Nonetheless, continued surveillance is mandatory to determine the lithiasis-inducing potential of these titanium staples

within the urinary tract. A prospective comparison between the conventionally fashioned and stapled constructed U-shaped ileal neobladder is warranted for more solid conclusions.^{11–13}

ACKNOWLEDGMENT. To Professor Lúcio F. Gonzaga, M.D., Ph.D., Chairman of Urology, Federal University of Ceará, for his support on developing this technique.

REFERENCES

1. Dall'oglio M, Nesrallah L, Rodrigues P, *et al*: The use of absorbable mechanical suture in orthotopic ileal neobladder replacement. *Braz J Urol* 26: 288–292, 2000.
2. Montie JE, Pontes JE, and Powell IJ: A comparison of the W-stapled ileal reservoir with hand-sewn reservoirs for orthotopic bladder replacement. *Urology* 47: 476–481, 1996.
3. Kerbl K, Chandhoke P, McDougall E, *et al*: Laparoscopic stapled bladder closure: laboratory and clinical experience. *J Urol* 149: 1437–1439, 1993.
4. Shalhav A, Dunn M, Portis A, *et al*: Laparoscopic nephroureterectomy for upper tract transitional cell carcinoma: the Washington University experience. *J Urol* 163: 1100–1104, 2000.
5. Grubb R, Robert L, Sundaram C, *et al*: Use of titanium staples during upper tract laparoscopic reconstructive surgery. *J Urol* 168(4, Part 1 of 2): 1366–1369, 2002.
6. Baughman S, Sexton W, and Bishoff J: Multiple intravesical linear staples identified during surveillance cystoscopy after laparoscopic nephroureterectomy. *Urology* 62: 351vi–351viii, 2003.
7. Abreu SC, Fonseca G, Gadelha JB, *et al*: Laparoscopic radical cystectomy with intracorporeally constructed Y-shaped ileal neobladder using non-absorbable titanium staples exclusively. *Urology* 66: 657.e15–657.e17, 2005.
8. Abreu SC, Messias F, Argollo R, *et al*: Laparoscopic assisted radical cystoprostatectomy with Y-shaped orthotopic ileal neobladder constructed using non-absorbable titanium staples through a 5 cm Pfannenstiel incision. *Int Braz J Urol* 31: 362–369, 2005.
9. Fontana D, Bellina M, Fasolis G, *et al*: Y-neobladder: an easy, fast, and reliable procedure. *Urology* 63: 699–703, 2004.
10. Abreu SC, Silveira RA, Cerqueira JB, *et al*: Stapleless laparoscopic assisted radical cystectomy with ileal neobladder in a male and with ileal loop in a female: initial report from Brazil. *Int Braz J Urol* 31: 214–221, 2005.
11. Abreu SC, and Gill I: Laparoscopic radical cystectomy, in Cadeddu J (Ed): *Laparoscopic Urologic Oncology*. Totowa, New Jersey, Humana Press, 2003, pp 297–304.
12. Moinzadeh A, and Gill I: Laparoscopic radical cystectomy with urinary diversion. *Curr Opin Urol* 14: 83–87, 2004.
13. Basillote J, Abdelshehid C, Ahlering T, *et al*: Laparoscopic assisted radical cystectomy with ileal neobladder: a comparison with the open approach. *J Urol* 172: 489–493, 2004.
14. Turk TM, Koleski FC, and Albala DM: Incidence of urolithiasis in cystectomy patients after intestinal conduit or continent urinary diversion. *World J Urol* 17: 305–307, 1999.
15. Terai A, Ueda T, Kakehi Y, *et al*: Urinary calculi as a late complication of the Indiana continent urinary diversion: comparison with the Kock pouch procedure. *J Urol* 155: 66–68, 1996.
16. Osther PJ, Poulsen AL, and Steven K: Stone risk after bladder substitution with the ileal-urethral Kock reservoir. *Scand J Urol Nephrol* 34: 257–261, 2000.
17. Stein J, and Skinner D: Orthotopic urinary diversion, in Walsh PC, Retik AB, Vaughan ED Jr, *et al* (Eds): *Campbell's Urology*, 8th ed. Philadelphia, WB Saunders, 2002, vol 4, pp 3835–3867.