

1



2

# 3

---

3

## Laparoscopic Radical Prostatectomy

4

**Sidney C. Abreu, Andrew P. Steinberg, and Inderbir S. Gill**

5

Cleveland Clinic Foundation, Cleveland, Ohio, USA

6

7

### 1. INTRODUCTION

8

Since Millin reported the first retropubic approach for prostate surgery in 1947 [1], the urological community has concentrated their efforts on learning and refining this technique. Although radical retropubic prostatectomy remains an intricate operation, several anatomical discoveries in the past twenty years have changed the face of this surgery. As such, it has evolved from an unpopular operation with significant morbidity into an anatomically precise dissection [2].

14

Recently, laparoscopy has been incorporated into the urological armamentarium as an alternative technique for the treatment of localized prostate cancer. Laparoscopic radical prostatectomy (LRP) aims to simulate the open retropubic approach [3]. Due to its enhanced visualization and magnification, laparoscopy has the potential to have a favorable impact on the morbidity and functional sequelae related to this operation.

20

In the initial report of LRP by Schuessler et al. in 1991 [4], the authors concluded that the laparoscopic procedure “offers no advantage over open surgery” mainly because of the extreme length of operative time (mean 9.4 hours) [5]. However, in the past 3 years, improvement in laparoscopic skills, confidence, and technology has turned LRP into an efficient day-to-day practice at selected centers. In this endeavor, enormous credit goes to the French team of Guillonneau

24 and Vallencien from Montsouris [6], who ultimately pioneered, and validated,  
25 the technique of LRP.

26 At our institution, we have been developing the technique of LRP to dupli-  
27 cate the principles of the open radical retropubic technique practiced in the United  
28 States today [7]. Our experience with LRP approaches 250 cases, and includes  
29 experience in both transperitoneal and extraperitoneal approach. In this chapter,  
30 we describe our step-by-step laparoscopic radical prostatectomy technique, high-  
31 lighting some modifications incorporated by our team and discussing how each  
32 step is related to the anatomical and functional outcome of this challenging proce-  
33 dure.

## 34 **2. PATIENT SELECTION**

35 Proper patient selection is paramount in achieving adequate surgical and oncologi-  
36 cal outcomes. As such, patients need to fulfill two sets of criteria.

### 37 **Criteria for Undergoing Radical Prostatectomy**

38 The laparoscopic approach follows the well-established oncological principles  
39 for the open radical prostatectomy. Therefore, like in most centers that routinely  
40 performed conventional open prostatectomy, this approach is reserved for patients  
41 with clinically localized prostate (T1, T2) cancer. The surgical treatment of ad-  
42 vanced stages (T3, T4) remains controversial.

### 43 **Criteria for Undergoing Laparoscopy**

44 Prior hormone treatment or localized radiation therapy will increase the potential  
45 for operative morbidity. However, in our experience, they are no longer a formal  
46 contraindication for the laparoscopic approach. A large prostate gland will also  
47 raise the level of technical difficulty. Nonetheless, we have performed this proce-  
48 dure successfully in patients with a prostate glands weighting up to 220 grams.  
49 Previous abdominal surgery, such as appendectomy, is not an absolute contraindi-  
50 cation for the laparoscopic technique either; however, difficulty may be encoun-  
51 tered while gaining intraperitoneal access. Extra care should be taken during  
52 initial trocar insertion. Obesity is not, in itself, a contraindication to the laparos-  
53 copic approach, although it significantly increases the level of technical difficulty.  
54 Our heaviest patient has weighted 350 pounds.

## 55 **3. PREOPERATIVE PREPARATION AND PATIENT POSITION**

56 Two bottles of magnesium citrate are self-administered by the patient at home  
57 on the afternoon before surgery. The patient reports to the hospital on the morning

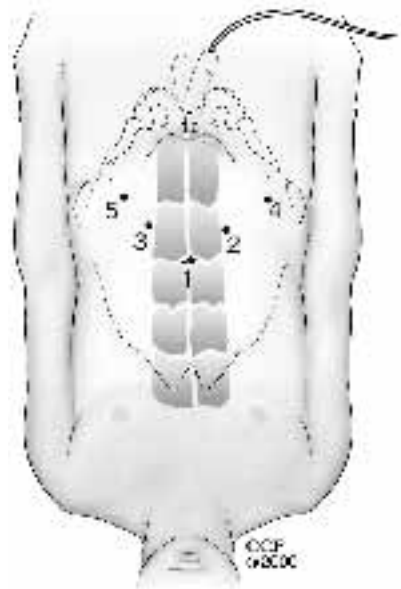
58 of the procedure. Broad-spectrum intravenous antibiotics and subcutaneous hepa-  
 59 rin are given. Bilateral sequential compression devices are placed routinely. The  
 60 patient is placed in a modified lithotomy position (thighs abducted) with the arms  
 61 adducted to facilitate simultaneous abdominal and perineal access. The abdomen,  
 62 penis, scrotum, upper thighs, and perineal region are prepared with iodine-based  
 63 disinfectant and draped. A Foley catheter is inserted in the sterile field and the  
 64 bladder drained. The table is set in a Trendelenburg position, with the degree of  
 65 head-down inclination varying depending on the proposed approach [8].

#### 66 4. PORT PLACEMENT

67 The Montsouris transperitoneal approach for LRP was described by Guillonneau  
 68 and Vallencien [8]; the reader is referred to their article for an in-depth description.

69 At the Cleveland Clinic, five ports are arranged in a “fan” configuration  
 70 in the pelvic area (Figure 1). In this port configuration, the surgeon uses the  
 71 12 mm port and the 5 mm port inserted respectively along the right and left lateral  
 72 border of the rectus muscle, approximately 2 fingerbreadths below the umbilicus.

F1



**FIGURE 1** For either the transperitoneal or the extraperitoneal approach, 5 ports are employed in a “fan” array.

73 5 mm ports are placed 2 fingerbreadths medial to each anterior superior iliac  
74 spine and are used by the assistant for retraction and suction purposes.

## 75 5. LAPAROSCOPIC ROUTE SELECTION

76 As the laparoscopic technique for radical prostatectomy evolved, three different  
77 approaches to the prostate gland were described. Initially, Guilloneau and  
78 Vallencien described a *transperitoneal posterior approach*, in which the dissec-  
79 tion initially commences at the rectovesical cul-de-sac [8]. A transverse peritoneo-  
80 tomy is created at the second peritoneal fold in the rectovesical cul-de-sac, and the  
81 seminal vesicles and vas deferens are mobilized circumferentially using bipolar  
82 electrocautery. At the Cleveland Clinic, we initially explored this posterior trans-  
83 peritoneal approach for LRP. However, in an attempt to bring the laparoscopic  
84 technique more in line with the open procedures, we shifted our technique to a  
85 pure *extraperitoneal approach* [11,12]. However, in our hands, the extraperitoneal  
86 approach allows a smaller working space and was found to be technically demand-  
87 ing and skill intensive [13]. Our current approach of choice for LRP is the *anterior*  
88 *transperitoneal approach* [14]. In this technique, no dissection is performed at  
89 the rectovesical cul-de-sac. Access to the Retzius' space is gained after the bladder  
90 is mobilized anteriorly. Although this modified route transgresses the peritoneal  
91 cavity, it allows the urologist a view with familiar landmarks and minimal bowel  
92 manipulation [10,14].

AQ1

## 93 6. SURGICAL TECHNIQUE

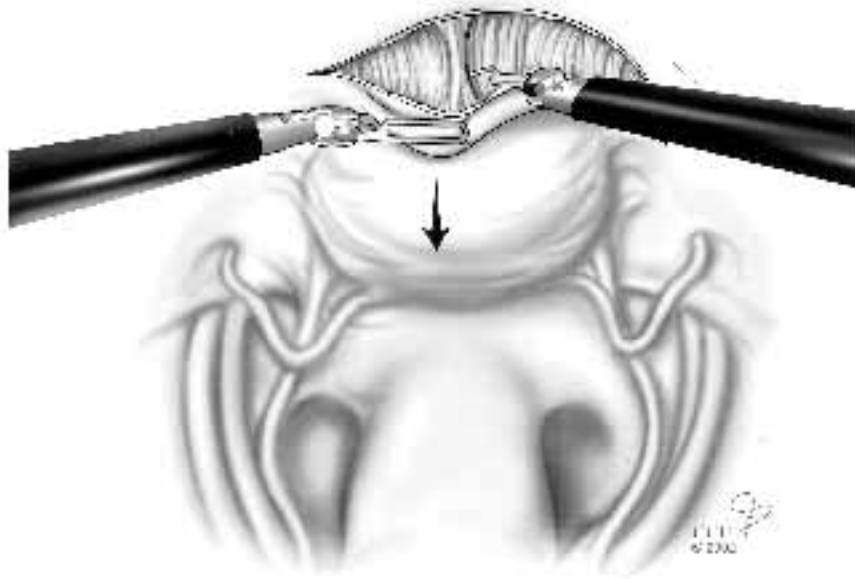
94 For the transperitoneal approach, the bladder is distended with 200 ml of saline  
95 through the indwelling Foley incision located medial to the ipsilateral medial  
96 umbilical ligament (Figure 2). The horizontal part of the U-incision is located  
97 high on the undersurface of the anterior abdominal wall. This helps to prevent  
98 inadvertent bladder injury and to preclude the parietal peritoneum from hanging  
99 in front of, and thereby compromising, the surgical view. Circumferential dissec-  
100 tion of the bladder is performed in a virtually avascular plane, involving dissection  
101 of delicate fibrofatty septae. Once the symphysis pubis has been visualized, the  
102 bladder is actively emptied using the bulb syringe. Dissection is initiated laterally  
103 on either side, completely exposing the endopelvic fascia bilaterally.

F2

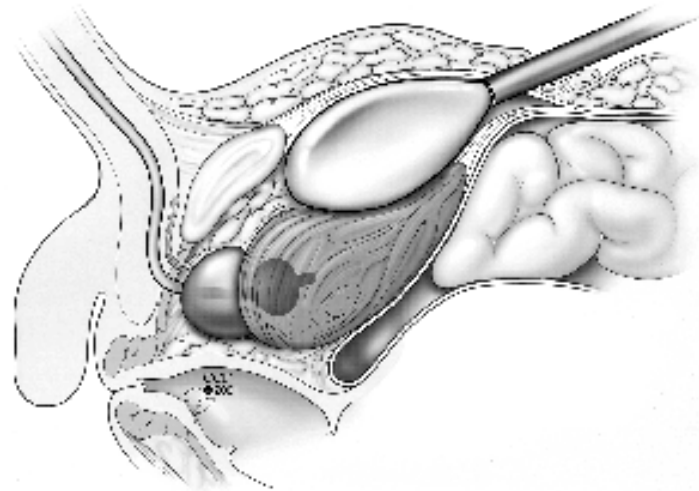
104 For the extraperitoneal approach, a trocar-mounted balloon dissection de-  
105 vice (US Surgical, Norwalk, CT) is used for rapid and atraumatic creation of a  
106 working space in the extraperitoneum (Figure 3).

F3

107 An incision is made on the anterior rectus fascia just below the umbilicus,  
108 and the trocar-mounted balloon is inserted and advanced down toward the pelvis  
109 under the rectus aponeurosis until the pubic bone is reached. At this point, the  
110 tip of the trocar is gently pushed underneath the pubic bone, entering the transver-



**FIGURE 2** Exposure of Retzius' space during the transperitoneal anterior approach. Any kind of dissection is no longer performed at the rectovesical space.



**FIGURE 3** Air is instilled into the balloon to develop the prevesical working space.

111 salis fascia to reach the prevesical space. Typically, only 200–300 ml of air are  
112 instilled into the balloon for inflation. The laparoscope is inserted to ensure the  
113 adequate positioning of the balloon.

114 Following dilation, the balloon is deflated and removed. A 10-mm Bluntip  
115 trocar (Origin Medsystems, Menlo Park, CA) is inserted as the primary port to  
116 assure an airtight seal, which, in our experience, is more difficult to achieve with  
117 a standard Hasson cannula [15].

118 After the puboprostatic ligaments and the endopelvic fascia on either side  
119 are exposed and the superficial dorsal vein is controlled, the prostate is retracted  
AQ2 120 tautly to the left side, placing the right endopelvic fascia on stretch. The endopel-  
121 vic fascia is incised distally up to the lateral-most puboprostatic ligament. Visual-  
122 ization of the apex of the prostate is the endpoint of this dissection. We minimize  
123 any dissection distal to the prostate apex, such as to not compromise this nerve-  
124 rich, sphincter-active zone.

125 The Foley catheter is replaced by an 18 Fr metallic urethral sound. A 2–0  
126 vicryl stitch with a CT-1 needle is employed to ligate the dorsal vein. This stitch  
127 is placed in a back-hand manner from the right to the left side, distal to the apex  
128 of the prostate, between the dorsal vein complex and the urethra. In order to  
129 avoid inadvertent transgression of the urethra by the suture, the assistant pushes  
130 down the metallic sound, displacing the urethra posteriorly. A back-bleeding  
131 stitch is placed across the anterior surface of the prostate base, and the tails of  
132 this stitch are cut somewhat long.

133 The long tails of the previously placed back-bleeding stitch are grasped  
134 and tautly retract anteriorly, thus elevating and “fixing” the base of the prostate.  
135 The bladder is tautly retracted cephalad, thereby placing the anterior bladder neck  
136 on traction. The precise anatomic location of the junction between the prostate  
137 and the bladder neck is not well defined under laparoscopic visualization. The  
138 absence of landmarks for the bladder neck identification is overcome by a combi-  
139 nation of maneuvers: close laparoscopic visualization usually identifies the area  
140 where the prevesical fat ends, signifying the prostatovesical junction. Gentle blunt  
141 dissection with the elbow of the J-hook electrocautery tip also aids to define this  
142 junctional area. Repeated in-and-out movements of the metallic urethral dilator,  
143 with its curved tip pointing anteriorly, provides another clue where the prostate  
144 ends and where the bladder begins.

145 At the presumed prostatovesical junction, a horizontal incision is created  
146 using J-hook electrocautery. The initial dissection aims to develop the plane lat-  
147 erally on each side of the bladder neck. The anterior bladder neck is divided in  
148 the midline, and the tip of the urethral dilator is delivered through the cystotomy  
149 into the space of Retzius.

150 Upon transecting the anterior bladder neck, the remaining posterior bladder  
151 neck is clearly seen. Using a J-hook electrocautery, the posterior bladder neck  
152 is scored away from the ureteral orifices. The posterior bladder neck is then

**Laparoscopic Radical Prostatectomy****131**

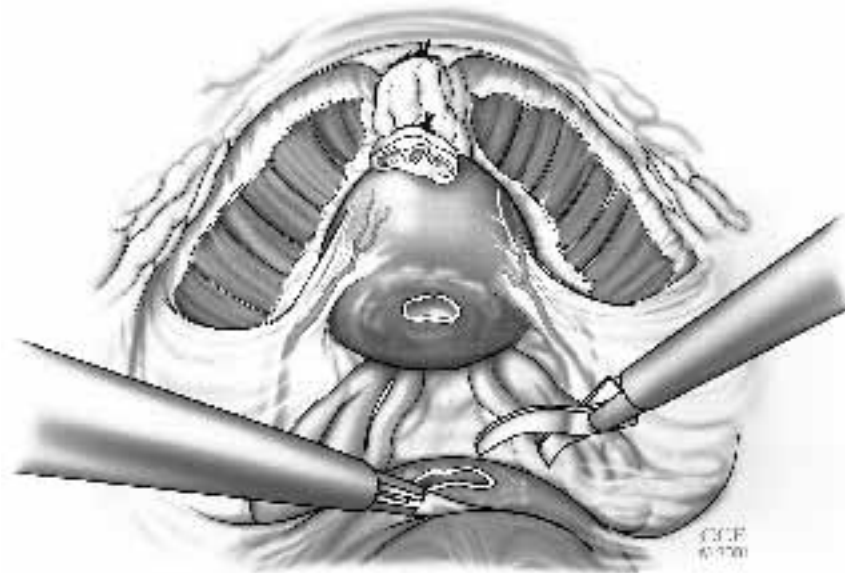
153 grasped in the midline with a laparoscopic Allis and gently retracted cephalad.  
 154 The plane between the posterior bladder neck and the prostate is developed with  
 155 a J-hook electrocautery. Care should be taken to avoid inadvertent creation of a  
 156 “button hole” on the posterior bladder wall.

157 We do not make a major effort to spare the bladder neck, which may result  
 158 in a positive surgical margin at this location. However, a carefully dissected  
 159 bladder neck can avoid the extra step of bladder neck reconstruction.

160 The incision on the posterior bladder neck is deepened for approximately  
 161 2–4 mm until the anterior layer of the Denonvilier’s fascia is encountered. The  
 162 surgeon must create a wide enough transverse incision to avoid “digging into a  
 163 hole.” The anterior layer of the Denonvilier’s fascia is incised and the vasa  
 164 deferentia are identified, grasped with a laparoscopic Allis clamp, and retracted  
 165 cephalad (Figure 4). Dissection is carried along its lateral border to identify the  
 166 ipsilateral seminal vesicle, which is mobilized circumferentially. The vesicular  
 167 vessels are carefully secured using a combination of harmonic scalpel and hemo-  
 168 lock clips. This is carried distally to its junction with the prostate.

169 The mobilized vas deferens and seminal vesicles are tautly retracted anteri-  
 170 orly, which places the posterior layer of Denonviliers’ fascia under traction. A

F4

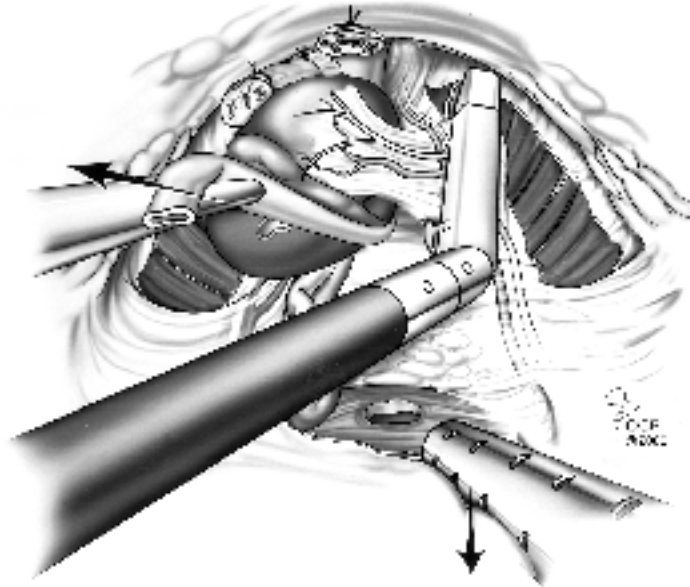


**FIGURE 4** The posterior bladder neck is incised. The posterior layer of Denonviliers’ fascia is entered and the vas deferens are identified.

171 small horizontal incision is created and enlarged with blunt dissection. Making  
 172 this incision approximately 2 to 3 mm posterior to the junction of the seminal  
 173 vesicles with the prostate allows proper entry into the prerectal plane posterior  
 174 to the prostate.

175 In a nonnerve-sparing procedure, while placing the adjacent lateral pedicle  
 176 on traction, an articulating Endo-GIA stapler (vascular cartridge, 2.5 mm) is fired  
 177 across each pedicle. A second Endo-GIA cartridge is employed to completely  
 178 detach the lateral border of the prostate and the neurovascular bundle from the  
 F5 179 perirectal fat (Figure 5). A similar maneuver is performed on the contralateral  
 180 side, leaving the prostate attached near its apex only.

181 The optimal technique of the nerve-sparing approach is still evolving. In  
 182 this regard, we have incorporated a few technical maneuvers to improve potency  
 183 outcome: (1) upon opening the endopelvic fascia, while releasing the levator  
 184 muscles from the apex and lateral aspect of the prostate, no thermal or electrical  
 AQ3 185 energy is used near the neurovascular bundle (NVB); (2) following dorsal vein  
 186 ligation, the lateral prostate fascia is bilaterally incised superficially with “cold”  
 187 Endoshears in order to release the tethering of the NVB; and (3) aiming to mini-  
 188 mize electrocautery trauma to the NVB near the tip of the seminal vesicles, by



**FIGURE 5** In a nonnerve-sparing procedure, an articulated Endo-GIA is used to widely transect the lateral pedicle and ipsilateral neurovascular bundle en bloc.

189 securing the vesicular artery with hemostatic locking clips (Weck Systems, Trian-  
190 gle Park, NC).

191 The nerve-sparing technique itself is performed in a combined antegrade-  
192 retrograde fashion. Initially, the lateral pedicles of the prostate are controlled with  
193 one or two 10 mm Hemolock clips (Weck Systems, Triangle Park, NC). The  
194 posterolateral edge of the prostate base is identified and the harmonic scalpel is  
195 employed to develop a plane between the gland and the NVB. The harmonic  
196 scalpel is preferred because of its limited spread of thermal energy (1–2 mm).  
197 We believe that further refinements in equipment that have no spread of any  
198 source of energy may lead to earlier recovery and higher rates of potency.

199 Using a laparoscopic Allis clamp, the transected base of the prostate is  
200 grasped with significant cephalad traction, placing the urethra and the dorsal vein  
201 complex on stretch. Subsequently, the harmonic scalpel is used to divide the  
202 dorsal vein complex along the curvature of the apex of the prostate. Occasionally,  
203 the dorsal vein stitch may loosen, leading to venous bleed. However, due to the  
204 tamponade effect of the CO<sub>2</sub> pneumoperitoneum, the degree of hemorrhage is  
205 usually not significant, and it is controlled by placing another stitch (2–0 vicryl,  
206 CT-1 needle) around the transected dorsal vein.

AQ4

207 After the dorsal venous complex is divided, the anterior urethral wall is  
208 identified with the aid of the metallic urethral sound. Cold Endoshears are used  
209 to transect the anterior urethral wall close to the concave notch of the prostate,  
210 which assures preservation of an excellent urethral stump. The tip of the intraure-  
211 thral metallic sound is delivered through the urethral opening. The posterior ure-  
212 thral wall and the rectourethralis muscles are divided. During this maneuver,  
213 which completely detaches the prostate, extreme care is taken to avoid inadvertent  
214 entry into the prostatic apex and rectum. The prostate is entrapped immediately  
215 in a 10 mm Endocatch bag (US Surgical, Norwalk, CT) and placed in the abdomen  
216 until extraction at the end of the case.

217 The bladder neck is evaluated closely and biopsied if there is suspicion  
218 that prostatic tissue was left behind. The ureteric orifices are assessed and if there  
219 is any doubt as to their integrity, intravenous indigo carmine can be administered.  
220 A running suture (UR-6 needle, 3–0 vicryl) is employed to tighten the posterior  
221 bladder neck if necessary. Due to the superb mucosa-to-mucosa laparoscopic  
222 urethrovesical anastomosis, bladder neck eversion is not performed [9].

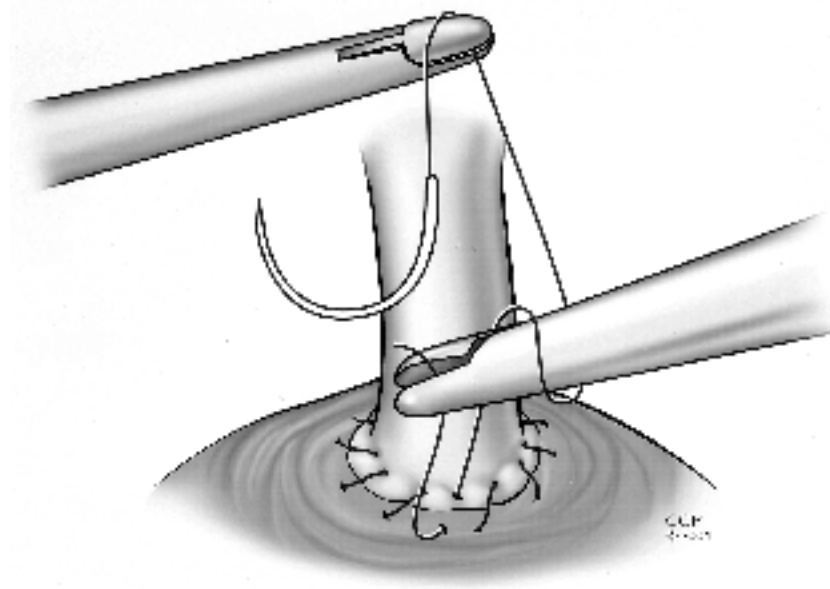
223 During open retropubic radical prostatectomy, the pubic bone impairs the  
224 visibility and access to the urethral stump, making the placement of sutures diffi-  
225 cult. In addition, the surgeon must tie the knots in a blind field and rely on tactile  
226 sensation alone. Comparatively, during laparoscopic radical prostatectomy, all  
227 sutures are meticulously placed and tied under complete visual control [16].

228 In our early experience, the urethrovesical anastomosis was performed with  
229 6 to 8 interrupted sutures. With increased laparoscopic suturing skills, we  
230 switched to a running suture technique in an attempt to decrease the anastomotic

231 time and postoperative urinary leak [16,17]. The running suture technique fre-  
 232 quently results in a watertight anastomosis immediately after the operation, and,  
 233 thus, the urethral Foley catheter can be removed safely as early as 2 to 4 postopera-  
 234 tive days [17].

235 Optimal preparation of the bladder neck and the urethral stump is paramount  
 236 for the adequacy of the urethrovesical anastomosis. Two full-thickness mucosa-  
 237 to-mucosa hemircumferential running sutures are placed in a preplanned, cho-  
 238 reographed sequence. Using 2 needle holders, an initial stitch (UR-6 with a 2-0  
 239 vicryl) is placed and tied at the 5 o'clock position, approximating the bladder  
 240 neck to the urethral stump. Subsequently, this suture is run in a clockwise direction  
 F6 241 to the 11 o'clock position (Figure 6), where it is pulled toward the symphysis pubis  
 242 and maintained under traction by an assistant. At least 3 to 4 needle passes are  
 243 necessary to create an adequate posterior plate. The metallic sound is used to  
 244 guide the needle, which glides into the urethra as the sound is retracted. A 22 Fr  
 245 urethral Foley catheter is advanced into the bladder. A second stitch is placed at  
 246 5 o'clock and run counterclockwise to 11 o'clock, where it is tied to the previous  
 247 placed stitch.

248 A Jackson-Pratt drain is inserted through one of the 5-mm port sites. The  
 249 specimen is extracted through an extension of the umbilical incision. Fascial



**FIGURE 6** Under excellent laparoscopic visualization, a precise mucosa-to-mucosa approximation is completed during the urethrovesical anastomosis using running suture technique.

**Laparoscopic Radical Prostatectomy****135**

250 closure of the 12 mm port site is achieved with a Carter-Thomason needle device  
251 and a 0 vicryl suture.

**252 7. INTRA-OPERATIVE DATA**

253 High operative blood loss and transfusion is a common problem of prostate sur-  
254 gery. A major advantage of the LRP is the potential to reduce operative blood loss.  
255 The magnified view of the dorsal venous complex provided by the laparoscope  
256 combined with the tamponading effect of the 15 mm Hg pressure of CO<sub>2</sub> pneu-  
257 moperitoneum are important factors which help decrease venous bleeding. The  
258 precise knowledge of the anatomy and the acquisition of experience by the sur-  
259 geon are also important issues related to the reduced blood loss during LRP [18].

260 In a review of 1228 LRP at 6 European centers, the average blood loss was  
261 488 mL with a transfusion rate of 3.5% [17]. The French team of Guillonneau  
262 and Vallancien also reported a mean intraoperative blood loss of 354 mL with  
263 a transfusion rate of 5.7% (20 patients) in a series of 350 LRP [18]. At the  
264 Cleveland Clinic, the average blood loss of our first 100 patients was only  
265 322 mL [19], resulting in transfusion of 2 patients (Table 1).

T1

**266 8. PERIOPERATIVE COMPLICATIONS**

267 The meticulous tissue handling and dissection during LRP have translated into  
268 low surgical and postoperative complications (Table 2) [18,19,30]. However,  
269 issues such as anastomotic leak and rectal injury require more attention and are  
270 discussed in further detail below.

T2

271 Anastomotic leak, which is usually defined as persistent extravasation at  
272 the anastomotic site for more than 7 days, occurs mainly because of the tear of  
273 the urethra by the suture at the anastomosis. During LRP, the magnified view  
274 may lead into an overestimation of the amount of tissue in the bite of the suture.  
275 Ideally, the depth of the suture is 4–5 mm on both bladder and urethral sides. In  
276 this manner, care must be taken to get sufficient width of tissue in the anastomosis  
277 [16].

278 Rectal injuries mainly occur when the rectourethralis muscle is divided  
279 after insufficient dissection between the rectum and the prostate, and less fre-  
280 quently when the posterior layer of Denonvilliers' fascia is incised [20]. The  
281 surgeon must take caution to avoid inadvertent rectal injury during these steps.  
282 Rectal injury must be immediately recognized and repaired to avoid further conse-  
283 quences.

**284 9. ONCOLOGIC RESULTS**

285 Concerns about the high rate of positive surgical margins after LRP, even in a  
286 select group of patients with organ-confined disease, have been raised [21]. We

**TABLE 1** Intraoperative Data

Author	Guillonneau(18)	Turk(30)	Hoznek(31)	Rassweiler(14)	Bollens(12)	Gill(19)
No. of patients	350	125	134	180	50	100
Approach	Transp.	Transp	Transp.	Transp.†	Extrap.‡	Transp Extrap
OR time (hr)	3.6	4.25	3.5*	4.5	4.4	4.5
Blood loss (cc)	354	185	—	1230	680	322
Transfusion rate	5.7%	2%	3%	31%	13%	2%
Open conversion	2%	0	0	4.4%	2%	1%

(\*) Excludes first 20 patients

(†) With immediate access to Retzius' space

(‡) Includes 8 transperitoneal procedures

**TABLE 2** Intraoperative and Postoperative Complications

	Guillonneau(20)	Turk(30)	Rassweiler(14)
No. of patients	567	125	180
Anastomotic stricture	–	2	6
Bladder injury	9	–	–
Ureteral injury	3	1	–
Ileus	6	4	5
Small bowel injury	2	1	–
Rectum injury	8	3	–
Rectourethral fistula	–	1	2
Epigastric injury	3	–	–
Iliac vein injury	–	1	–
Thrombosis*	2	3	–
Wound dehiscence	4	–	1

\* Although, the combination of pelvic surgery, laparoscopic procedure, and cancer increases the risks of thrombosis, this is not clinically observed probably due to the prevention based on antithrombotic profilaxis, compression stockings, and early patient mobilization.

287 do agree that a rightfully strict inclusion criteria was employed by laparoscopic  
 288 surgeons in their initial experiences, which may explain the larger percentage of  
 289 organ-confined disease (surgical pathology) after LRP when compared with some  
 290 large, open prostatectomy series. In regard to surgical margins status, we do  
 291 believe that laparoscopy will likely be comparable to open surgery. To support  
 292 this, our preliminary data show a drop of almost 50% on the positive surgical  
 293 margin from our first 50 cases to our third 50 cases [19]. Refinements of our  
 294 technique, especially the pristine dissection of the apex, were intrinsically related  
 295 to this significant decrease on the rate of positive surgical margins.

296 Because definitive cure of prostate cancer needs a long follow-up, current  
 297 available data are still quite immature. However, LRP is likely to emerge as a  
 298 sound oncological alternative. Salomon and colleagues have reported a projected  
 299 Kaplan-Meier biochemical (i.e., PSA) recurrence-free likelihood of 84% at three  
 300 years (91% for organ-confined tumor and 81% for pT3 tumors) [22]. Guillonneau  
 301 et al. have shown that in a subset of 250 patients who have undergone LRP,  
 302 serum PSA remained less than 0.2 ng/mL [23]. More recently, Guillonneau and  
 303 colleagues reported an oncological midterm evaluation of 1000 patients who  
 304 underwent LRP. The overall actuarial biochemical progression-free survival was  
 305 90.5% at 3 years. According to the pathological stage, the progression-free sur-  
 306 vival was 91.8% for pT2aN0, 88% for pT2bN0, 77% for pT3aN0 and 44% for  
 307 pT3bN0. Patients with negative surgical margins had 94% progression-free sur-  
 308 vival, while those with positive margin status had 80% (p <0.001) [24].

309 **10. FUNCTIONAL OUTCOME**310 **10.1 Urinary Continence**

311 The laparoscopic technique has the potential to improve the postoperative conti-  
312 nence rates due to the outstanding urethrovesical anastomosis performed under  
313 laparoscopic visualization. Guillonneau et al. reported on their first 133 patients  
314 with at least a 1-year follow-up and found 85.5% were totally continent (no  
315 protection needed during day or night) [18]. Five patients (3.8%) were classified  
316 as severely incontinent. Nadu et al. have reported continence rates greater than  
317 93% in a median follow-up of 7 months (range from 1 to 15). In this particular  
318 study, the urethrovesical anastomosis was performed with a single circular run-  
319 ning 3–0 polyglactin stitch. Only 15.1% of the patients had anastomotic leak on  
320 postoperative day 2–4 cystography. No anastomotic stricture, pelvic abscess, or  
321 urinoma were noticed in this series [17].

322 **10.2. Potency**

323 The anatomical course of the neurovascular bundles is well known, yet it is often  
324 difficult to preserve one or both nerves. Laparoscopy, with its unparalleled vision  
325 allows for excellent identification and handling of the neurovascular bundles.  
326 The potential to improve on postoperative potency rates exists, but outcome data  
327 with nerve-sparing techniques of LRP are sparse. Guillonneau et al. reviewed 73  
328 of their patients who had either bilateral (46 patients) or unilateral (27 patients)  
329 nerve-sparing LRP [25]. An impressive 74% spontaneous erection rate was re-  
330 ported in the bilateral nerve-sparing group, and 51% in the unilateral group, where  
331 a follow-up ranging from 2 to 12 months was employed. Bollens et al. had a  
332 9-month potency rate of 75% in patients who were potent preoperatively [26].  
333 Salomon and colleagues describe a one-month positive erection rate in 40% of  
334 patients with bilateral nerve-sparing, and in 22.2% of patients with unilateral  
335 nerve-sparing procedures [27]. More recently, Katz et al. reported a postoperative  
336 potency rate at 1 year in 87.5% of patients with bilateral nerve-sparing [28]. These  
337 authors found that the overall rate of patients who had erections preoperatively and  
338 maintained erections after surgery (53.8%) was comparable to the overall rate  
339 for patients who underwent open surgery.

340 **11. CONCLUSION**

341 The lessons learned with laparoscopic renal surgery may not be valid for laparos-  
342 copic prostatectomy. From the very initial cases with laparoscopic renal surgery,  
343 it was apparent that morbidity was markedly reduced [29]. With laparoscopic  
344 radical prostatectomy, the avoidance of a low midline incision may not have the  
345 same implications, and further prospective studies are necessary. Nonetheless,

**Laparoscopic Radical Prostatectomy****139**

346 diminished blood loss, excellent length of urethral stump, superb watertight ur-  
 347 ethrovesical anastomosis, and unparalleled visualization of the neurovascular bun-  
 348 dles provided by the laparoscopic technique may allow this minimally invasive  
 349 approach to overcome the already higher outcomes obtained with open radical  
 350 prostatectomy.

351

**EDITORIAL COMMENTARY**352 **Joseph R. Wagner and Caner Z. Dinlenc**

353 This chapter is an excellent review of Dr. Inderbir Gill's team's technique and  
 354 experiences performing laparoscopic radical prostatectomy at the Cleveland  
 355 Clinic. Just as any manuscript deservedly credits Dr. Patrick Walsh for his innova-  
 356 tions and insights in performing retropubic radical prostatectomy, the authors  
 357 rightfully cite the Montsouris group for their pioneering efforts proving laparos-  
 358 copic radical prostatectomy is a safe, effective surgical option for localized pros-  
 359 tate cancer. Currently, experienced laparoscopic groups are modifying their tech-  
 360 nique as they strive to maximize cancer control and long-term quality of life  
 361 outcomes and minimize surgical morbidity. As we proctor experienced open  
 362 surgeons in the laparoscopic procedure, we continue to take home "pearls" that  
 363 we have successfully applied to our own laparoscopic and robotic radical prosta-  
 364 tectomy technique. This chapter successfully shares this philosophy and makes  
 365 many excellent statements on the procedure.

366 As evidenced by the first report on laparoscopic radical prostatectomy by  
 367 Schuessler et al. in 1992 [1], laparoscopic radical prostatectomy is a technically  
 368 demanding procedure. Before even an experienced laparoscopic surgeon attempts  
 369 the procedure, we would recommend three steps of preparation that we believe  
 370 can dramatically decrease the "learning curve."

1. Assemble a team: Laparoscopic radical prostatectomy cannot be performed by one surgeon. The assistant surgeon should understand and be able to perform the necessary laparoscopic maneuvers to perform the procedure. Ideally, this surgeon should also have a firm understanding of laparoscopy and pelvic anatomy. In the operating room, nurses familiar with the equipment and anesthesiologists well versed in the physiologic considerations of what will at first be a lengthy laparoscopic procedure are critical.
2. Observation: Take courses to enhance your skills and understanding of the procedure and visit institutions performing the procedure, noting set-up, technique, etc., to optimally prepare your team.
3. Proctor: For both the laparoscopic and robotic approach, we found that having an experienced surgeon in the room to provide verbal suggestions

was invaluable during our first few cases. An increasing number of institutions are requiring that initial cases are proctored/mentored to gain credentials for complex laparoscopic procedures. Though this may seem like an obstacle, we have seen from both trainee and proctor the enormous benefits in terms of reducing the initial learning curve [2].

371 While we, too, do not place limits on patient size, prostate size, or the presence  
372 of a large median lobe, all of these can impact the ease of the procedure. Initially,  
373 “ideal patients” should be selected. Our patient preparation and positioning is the  
374 same, and we agree both compression stockings and 5,000 units of subcutaneous  
375 heparin are recommended for DVT prophylaxis.

376 The first step after establishing pneumoperitoneum and port placement  
377 using the Montsouris technique is to incise the second peritoneal reflection, dissect  
378 the seminal vesicles and vasa, and finally transect the vasa. As discussed, some  
379 surgeons are abandoning this portion of the procedure and dissecting the seminal  
380 vesicles and vasa after transecting the bladder neck. Performing the bladder neck  
381 transection first is felt to decrease bowel manipulation and, in some hands, de-  
382 crease the length of the procedure slightly. While we feel it is important to eventu-  
383 ally learn this approach, as it will be necessary in certain patients in whom the  
384 second peritoneal reflection is obliterated, such as in diverticulitis, we recommend  
385 initially identifying the seminal vesicles at the beginning of the procedure. The  
386 two most difficult parts of the procedure are identifying and then transecting the  
387 bladder neck and the anastomosis. Encountering an open space and the already  
388 dissected seminal vesicles after transecting the bladder neck is helpful and reassuring  
389 to the inexperienced surgeon. The extraperitoneal approach is desirable for  
390 similar reasons, but should be approached cautiously by the inexperienced sur-  
391 geon as the decreased room to operate can be problematic.

392 Although the pneumoperitoneum can temporarily tamponade venous inju-  
393 ries, meticulous control of the venous complex is a necessity in open radical  
394 prostatectomy. In addition to placing a urethral sound and pushing posteriorly to  
395 place the dorsal vein stitch, we find this maneuver very useful to stretch the  
396 urethra and aid in dissecting the apex.

397 The steps of robotic laparoscopic radical prostatectomy are similar with  
398 some advantages and disadvantages. Suturing is certainly easier, especially for  
399 an inexperienced laparoscopist, with the robot. Performing the procedure while  
400 sitting at a console avoids many of the musculoskeletal complaints associated  
401 with prolonged laparoscopic procedures. Disadvantages include the inability to  
402 manipulate the surgical table and patient position once the robot is in place and  
403 some loss of tactile sensation compared with the straight laparoscopic approach.

404 Despite increased visualization and decreased blood loss, laparoscopic pros-  
405 tatectomy outcome studies have not shown improved erectile function and conti-  
406 nence compared to open studies. While the authors cite all the appropriate refer-

**Laparoscopic Radical Prostatectomy****141**

407 ences, we continue to be distressed by the lack of prospective analysis using  
 408 validated questionnaires. Statements such as “achieving spontaneous erections”  
 409 or “continent without pads” should no longer be sufficient when excellent vali-  
 410 dated questionnaires such as the UCLA Prostate Index exist. It is incumbent upon  
 411 us to obtain these data to arrive at appropriate conclusions. Although intraopera-  
 412 tive blood loss is also a frequently cited outcome, we believe comparisons of  
 413 preoperative and discharge hemoglobins would be more reliable. As for surgical  
 414 margins, we have seen our rates drop approximately 9% using the laparoscopic  
 415 approach compared to our open series, although this has not been the experience  
 416 at all institutions.

417 Laparoscopic radical prostatectomy has been shown to be a feasible, safe,  
 418 and reliable procedure with outcomes similar to open series thus far. While we  
 419 believe we can now safely state that blood loss is less than in the open procedure,  
 420 comparisons of surgical morbidity, long-term PSA outcomes, and quality of life  
 421 issues must be evaluated. The laparoscopic approach has been shown to decrease  
 422 the morbidity and convalescence associated with numerous open procedures, such  
 423 as nephrectomy and adrenalectomy. Whether this will hold true for radical prosta-  
 424 tectomy remains to be seen. The authors are to be congratulated for this chapter,  
 425 which describes their superb technique and outcomes, as well as begins to answer  
 426 some of these important questions.

427

**REFERENCES**

- 428 1. Schuessler WW, Kavoussi LR, Clayman RV, Vancaille T. Laparoscopic radical pros-  
 429 tatectomy; initial case report. J Urol 1992; 246A.
- 430 2. Dinlenc C, Wagner J. Laparoscopic Radical prostatectomy: decreasing the learning  
 431 curve, Abstract presented at the World Congress of Endourology, September 19–21,  
 432 2002, Genoa, Italy.

433

**EDITORIAL COMMENTARY**434 **Bertrand Guillonau**

435 Department of Urology, Memorial Sloan Kettering Cancer Center, New York, New  
 436 York, USA

437 The chapter, “Laparoscopic Radical Prostatectomy,” summarizes perfectly what  
 438 is known and what is not known by urologic teams involved in the laparoscopic  
 439 approach to “modern” radical prostatectomy.

440 The facts here are obvious and bolster the faith of each surgeon who has  
 441 already begun the laparoscopic approach.

442

### **THE APPROACH IS MINIMALLY INVASIVE**

443 Incisional pain for the patient is reduced to a minimum, thus allowing a more  
444 comfortable and shorter hospital stay and quicker return to normal activities than  
445 with open radical prostatectomy. In addition, even if it has not been evaluated  
446 in the various series, recovery for the patient is surprisingly rapid.

447       These advantages are related to the less-traumatizing surgical approach to  
448 the prostate, one that makes no significant abdominal wound. Where surgery is  
449 ablative, this advantage is common to all laparoscopic procedures, as opposed  
450 to conventional ones, from cholecystectomy to nephrectomy.

451

### **THE VIEW IS IMPROVED**

452 There are three main reasons for this improvement. The first and most obvious  
453 one is that the camera provides an approximately 15-fold magnification of the  
454 operative field. The second reason is related to the improvement in ergonomics  
455 for the surgeon: instead of remaining deep inside, the prostate becomes directly  
456 visible on the monitor screen. The third element contributing to the improvement  
457 of view is the reduction of bleeding, confirmed objectively in all series by the  
458 observation that both the estimated blood loss and the transfusion rates are low-  
459 ered. Certainly, the counter-pressure of the pneumoperitoneum helps, but because  
460 of the magnification and improved ergonomics, the surgeon can see and control  
461 the vessels more efficiently before they bleed, allowing the surgeon to operate  
462 in an almost dry operative field, which leads again to a much-improved operative  
463 view.

464       A more perfect vision is part of the concept of the laparoscopic approach,  
465 because, as its detractors often aver, tactile sense is decreased compared with  
466 the direct digital palpation of other methods. This handicap, however, is largely  
467 compensated for by the improved view. Improved vision is a major advantage  
468 in surgery, in general, and in prostatectomy in particular, as this procedure is not  
469 only ablative, but also reconstructive and functional.

470

### **THE QUALITY OF THE URETHROVESICAL ANASTOMOSIS IS IMPROVED**

472 This occurs no matter what suturing technique is used, whether running or inter-  
473 rupted. The procedure allows a good anastomosis of the orifices, and, therefore,  
474 a quicker healing time, as the short catheterization time demonstrates.

475       Nevertheless, the questions, or shadow areas, are numerous. But the dedica-  
476 tion of these teams to this procedure is still justified, as long as there is a proper  
477 evaluation of it.

478

**APPROACH**

479 As mentioned in this chapter, three routes can be used to perform a radical prosta-  
480 tectomy laparoscopically, and all are probably justified, depending on the patient,  
481 the tumor, and the experience of the surgeon.

482 Whenever the Douglas pouch is accessible and I want to perform a nerve-  
483 sparing procedure, I first do a direct approach to the seminal vesicles. Transperito-  
484 neally, the seminal vesicles are made superficially visible and are then easily  
485 accessible. The approach to them is quicker and safer because dissection is much  
486 more accurate. There is no traction on the vascular pedicles and they are controlled  
487 directly, so the risk of injury to the neural network in this area is limited. Further-  
488 more, in my experience, the dissection of the seminal vesicles through the bladder  
489 neck requires more traction on the seminal vesicles and, therefore, on their pedi-  
490 cles, and a more lateral transection of the prostate pedicles, which might injure  
491 the neurovascular bundles in this area.

492 To summarize my approach, I first dissect the seminal vesicles when I want  
493 to do a nerve-sparing procedure. Otherwise, I agree with the authors on the value  
494 of the “anterior transperitoneal approach.” Because surgery should be adapted  
495 to the patient and its disease one approach doesn’t generally fit every situation.  
496 With this concern, the pure extraperitoneal approach is less flexible while the  
497 transperitoneal approach allows a better adaptation case by case.

498

**THE STRATEGY OF DISSECTION**

499 In general, some surgeons promote a pure retrograde dissection approach, mim-  
500 icking Walsh’s technique. I believe that, in laparoscopy, antegrade dissection is  
501 more adaptive as the dissection is always in the axis of the surgeon’s view and  
502 the instruments, allowing dissection without any traction on the periprostatic  
503 structures, particularly the neurovascular bundles. For these reasons, the antegrade  
504 approach seems, to me, more logical.

505

**INSTRUMENTATION**

506 Each team has developed its own instrumental tactic, from the simplest use of  
507 very few instruments—which I advocate—to use of the most complicated sys-  
508 tems, like remote-controlled telemanipulators.

509 I use only bipolar forceps to control vessels. This kind of cautery is very  
510 effective on veins and arteries; has limited thermal diffusion, if vessel control is  
511 accurate; and the instruments needed are inexpensive, widely available, and reusa-  
512 ble. At present, the real question is not what is the best energy source, or what  
513 is the best brand of clip to control the vessels without damaging the nerves!  
514 Instead, it is where should the vessels be controlled so that they are far enough

515 away for the nerves to be safe when the instrument is applied. The debate, here,  
516 is more anatomical than instrumental.

517

### CANCER CONTROL

518 Control of the cancer is the primary goal of radical prostatectomy, and the best  
519 assessment of the quality of the surgery is based on the absence of positive  
520 margins in the biopsy specimen. Surprisingly, the positive-margin rate in laparos-  
521 copic surgery seems to be roughly comparable to the retropubic procedure. Half  
522 of the margins are apical, supporting the notion that, at this location, positive  
523 margins are more likely to be due to the disease itself and to the absence of  
524 capsule in this area rather than to the surgical technique. The other sites of positive  
525 surgical margins are posterolateral, pedicular, anterior, and, more rarely, at the  
526 bladder neck. Therefore, for progress in this area, it is mandatory to limit these  
527 pitfalls as much as possible. We should admit that even the improved view is  
528 clearly not sufficient to diagnose positive margins. Because of this, I prefer to  
529 extract the specimen as soon as the prostatectomy is completed and to examine  
530 it carefully under direct vision and palpation. Anytime I have a suspicion of  
531 positive margins, frozen-section examination is performed on the specimen, and,  
532 if positive, a wider excision is made in the area of concern.

533

### URINARY FUNCTION

534 Broad-spectrum antibiotic therapy is not necessary in all patients, and I have  
535 given up on systematic antibiotic prophylaxis, which I prescribe only to patients  
536 with previous history of urinary infection. The question of what is the ideal  
537 duration of catheterization has yet to be answered. It is clear that, in some patients,  
538 the catheter can be removed as soon as the second postoperative day. However,  
539 selection of these patients is difficult. Early removal of the catheter exposes  
540 patients to acute retention, with makes recatheterization necessary. Even more  
541 severe complications, like extravasation, are possible if early removal becomes  
542 the rule. In fact, a prudent attitude is to let the catheter remain at least 4 days.

543 The evaluation of continence after laparoscopy is as difficult as after retro-  
544 pubic prostatectomy because there is no single questionnaire that is widely ac-  
545 cepted and used. In addition, the definition of continence varies among series.  
546 Nevertheless, the published data suggests that the 12-month results are in the  
547 same range as after retropubic prostatectomy—80 to 90%—but the question of  
548 the speed of recovery is still debatable, as no prospective studies have been  
549 published.

550

### SEXUAL FUNCTION

551 The technique of neurovascular dissection varies widely from one surgeon to  
552 another, and, even in the most experienced of hands, the technique is still evolving.

**Laparoscopic Radical Prostatectomy****145**

553 It is, therefore, not surprising that the results vary so widely in the different  
 554 published series. Furthermore, evaluation of potency is one of the blurriest fields  
 555 of evaluation in urology because a single definition of erection itself is not com-  
 556 monly accepted and different questionnaires are used for evaluation. Nonetheless,  
 557 the experiences of many surgeons have confirmed that nerve-sparing surgery is  
 558 technically feasible and functionally efficient. Furthermore, there are some data  
 559 suggesting that the recovery time of erection is shortened, probably because mag-  
 560 nification and the operative strategy allow a less-traumatizing dissection of the  
 561 fragile structures of the neurovascular bundles.

562 In conclusion, laparoscopy is just one approach, and certainly not the only  
 563 solution, to the problems involved in radical prostatectomy. Some problems are  
 564 solved through its use; for example, pain, the quality of the urethrovesical anasto-  
 565 mosis, and blood loss. But the problems of cancer control and functional results  
 566 remain. Nevertheless, I am confident that this technique will finally solve more  
 567 problems than it creates and will add to the global improvement of surgery for  
 568 prostate cancer. If this occurs, there is no doubt that laparoscopy will become,  
 569 in the near future, the reference approach for radical prostatectomy.

570

**EDITORIAL OVERVIEW**571 **Kenneth B. Cummings**

572 Significant progress has occurred in the performance of Laparoscopic Radical  
 573 Prostatectomy (LRP) since the original report by Schuessler et al. in 1992 [1],  
 574 in which the authors concluded that because of the protracted operative time  
 575 (mean, 9.4 hours), LRP “offers no advantage over open surgery.” Gill and coau-  
 576 thors appropriately credit the French team of Guillonneau and Vallencien from  
 577 Montsouris who brought LRP to contemporary practice [2,3].

578 In contrast to the original approach by the Montsouris team to the seminal  
 579 vesicles, Gill prefers to transect the vesicle neck before identifying and dissecting  
 580 the seminal vesicles. Their nerve sparing technique, which is still evolving, is  
 581 performed in a combined antigrade–retrograde fashion. The urethral anastomosis  
 582 is performed utilizing a 2-0 Vicryl suture on UR-6 needle “at least 3 to 4 needle  
 583 passes with subsequent sinching are necessary in order to bring into apposition  
 584 the vesical urethral junction.” Margin positivity is considered by this group to  
 585 be experience and operator dependent, as demonstrated by a drop of almost 50%  
 586 in the positive surgical margins from their first 50 cases to their third 50 cases  
 587 in their series. Urinary incontinence in their series appears competitive to open  
 588 surgery. Potency rates are not competitive to the “best open RRP series.”

589 Guillonneau focuses on the obvious advantages of LRP: (a) the approach  
 590 is minimally invasive, allowing a more rapid return to normal activities than open  
 591 radical prostatectomy; (b) the operator’s vision is dramatically improved because

AQ5

592 of camera magnification as well as the ergonomics (the prostate, which, in open  
593 surgery, is viewed deep in the pelvis in contrast to laparoscopic surgery, in which  
594 it is displayed magnified on a screen); (c) importantly, the pneumoperitoneum  
595 dramatically reduces venous bleeding, improving over all vision, and, with magni-  
596 fication, permitting more precise dissection and cauterization of blood vessels;  
597 and (d) improved quality of the vesicourethral anastomosis, permitting earlier  
598 removal of the catheter.

599 Of note, Guillonneau, for nerve sparing, prefers to initially dissect the semi-  
600 nal vesicles in the pouch of Douglas when this is not obliterated by adhesions (i.e.,  
601 diverticulities). Guillonneau stresses the importance of the antigrade dissection  
602 approach in laparoscopy in contrast to the pure retrograde technique of Walsh.  
603 His observation is that, in laparoscopy, the axis of dissection is in the direction  
604 of the surgeon's view.

605 Guillonneau contends that, with time and experience, LRP should produce  
606 equal cancer-control continence and potency and may become the referenced  
607 approach to radical prostatectomy.

608 Wagner and Dinlenc wisely focus on the steep learning curve for LRP and  
609 highlight approaches to shorten the duration of this learning curve and achieve  
610 technical improvement. They consistently favor the initial dissection of seminal  
611 vesicles when this is technically feasible. Nerve sparing is performed antigrade  
612 and the urethral anastomosis is performed with interrupted sutures.

613

## REFERENCES

- 614 1. Schuessler WW, Kavoussi LR, Clayman RV, Vancaille T. Laparoscopic radical pros-  
615 tatectomy: initial case report. *J Urol* 1992; 147:246A.
- 616 2. Guillonneau B, Vallancien G. Laparoscopic radical prostatectomy: the Montsouris  
617 experience. *J Urol* 2000; 163:418–422.
- 618 3. Guillonneau B, Vallancien G. Laparoscopic radical prostatectomy: the Montsouris  
619 technique. *J Urol* 2000; 163:1643–1649.

620

## REFERENCES

- 621 1. Millin T. *Retropubic Urinary Surgery*. London: Livingstone, 1947.
- 622 2. Walsh PC, Donker PJ. Impotency following radical prostatectomy: insight into etiolo-  
623 gy and prevention. *J Urol* 1982; 128:492–497.
- 624 3. Andriole GL. Laparoscopic radical prostatectomy. *Con Urology* 2001; 58:507–508.
- 625 4. Schuessler WW, Kavoussi LR, Clayman RV, Vancaille T. Laparoscopic radical  
626 prostatectomy: initial case report. *J Urol* 1992; 147:246A.
- 627 5. Schuessler W, Shulman P, Clayman RV. Laparoscopic radical prostatectomy: initial  
628 short-term experience. *Urology* 1997; 50:854.
- 629 6. Guillonneau B, Vallancien G. Laparoscopic radical prostatectomy: the Montsouris  
630 experience. *J Urol* 2000; 163:418–422.

## Laparoscopic Radical Prostatectomy

147

- 631 7. Sung G, Meraney A, Zippe C, Gill S. Technical improvements in laparoscopic radical  
632 prostatectomy. *J Urol* 2001; 165(Suppl):181.
- 633 8. Guillenneau B, Vallancien G. Laparoscopic radical prostatectomy: the Mountsouris  
634 technique. *J Urol* 2000; 163:1643–1649.
- 635 9. Gill I, Zippe C. Laparoscopic radical prostatectomy: technique. *Urol Clin North Am*  
636 2001; 28:423–436.
- 637 10. Steinberg A, Gill I. Laparoscopic radical prostatectomy. *Contemporary Urol* 2002;  
638 14:34–49.
- 639 11. Raboy A, Ferzli G, Albert P. Initial experience with extraperitoneal endoscopic  
640 radical retropubic prostatectomy. *Urology* 1997; 50:849–853.
- 641 12. Bollens R, Bossche MV, Roumeguere T, Damoun A, Ekane S, Hoffmann P, Zlotta  
642 AR, Schulman CC. Extraperitoneal laparoscopic radical prostatectomy. *Eur Urol*  
643 2001; 40:65–69.
- 644 13. Abreu S, Gill I, Kaouk J, Matin S, Meraney A, Farouk A, Steinberg A, Desai M,  
645 Zippe C, Sung G. Laparoscopic radical prostatectomy: comparison of transperitoneal  
646 versus extraperitoneal approach. *J Urol* 2002; 167(4, Suppl):19.
- 647 14. Rassweiler J, Sentker L, Seemann O, Hatzinger M, Rumpelt HJ. Laparoscopic radical  
648 prostatectomy with the Heilbronn technique: an analysis of the first 180 cases. *J*  
649 *Urol* 2001; 166:2101–2108.
- 650 15. Gill S. Retroperitoneal laparoscopic nephrectomy. *Urol Clin North Am* 1998; 25:  
651 343.
- 652 16. Hoznek A, Salomon L, Rabii R, Slama MB, Cicco A, Antiphon P, Abbou CC.  
653 Vesicourethral anastomosis during laparoscopic radical prostatectomy: the running  
654 suture method. *J Endourol* 2000; 14:749–753.
- 655 17. Nadu A, Salomon L, Hoznek A, Olsson LE, Saint F, Taile A, Cicco A, Chopin D,  
656 Abbou CC. Early removal of the catheter after laparoscopic radical prostatectomy.  
657 *J Urol* 2001; 166:1662–1664.
- 658 18. Guillonneau B, Cathelineau X, Doublet JD, Vallancien G. Laparoscopic radical pros-  
659 tatectomy: the lessons learned. *J Endourol* 2001; 15:441–445.
- 660 19. Farouk A, Gill I, Kaouk J, Matin S, Meraney A, Desai M, Abreu S, Steinberg A, AQ6  
661 Zippe C, Sung G. 150 laparoscopic radical prostatectomy (LRP): learning curve in  
662 the United the States. *J Endourology* 2002; 16(Suppl 1, A33):P9–2.
- 663 20. Guillenneau B, Rozet F, Cathelineau X, Frank L, Barret E, Doublet JD, Baumert H,  
664 Vallancien G. Perioperative complications of laparoscopic radical prostatectomy: the  
665 Montsouris 3-year experience. *J Urol* 2002; 167:51–56.
- 666 21. Walsh PC. Minimally invasive treatment of prostate cancer. *J Endourol* 2001; 15:  
667 447–448.
- 668 22. Salomon L, Hoznek A, Saint F, Cicco A, Antiphon P, Chopin DK, Abbou CC.  
669 Oncologic results of 100 consecutive laparoscopic radical prostatectomies. *J of Urol*  
670 2001; 165(Suppl):1442A.
- 671 23. Guillonneau B, Cathelineau X, Doublet JD, et al. Short-term oncological follow-up AQ7  
672 results of laparoscopic radical prostatectomy in prostate cancer with PSA<11 ng/  
673 mL and Gleason score = 6. *J of Urol* 2001; 165(Suppl):1346A.
- 674 24. Guillonneau B, el Fettouh H, Baumert HC. Laparoscopic radical prostatectomy: AQ8  
675 oncological miditerm evaluation about 1000 patients at Montsouris Institute. *J En-  
676 dourology* 2002; 16(Suppl 1, A36):P9–13.

- AQ9 677 25. Guillonneau B, Cathelineau X, Doublet JD, et al. Prospective assesment of functional results after laparoscopic radical prostatectomy. *J of Urol* 2001; 165(Suppl):  
678 614A.  
679
- AQ10 680 26. Bollens R, Bossche MV, Roumeguere T, et al. Laparoscopic radical prostatectomy:  
681 analysis of the first series of extraperitoneal approach. *J of Urol* 2001; 165(Suppl):  
682 1354A.
- 683 27. Salomon L, Olsson LE, Hoznek A, Antiphon P, Cicco A, Chopin DK, Abbou CC.  
684 Continence and potency after laparoscopic radical prostatectomy. *J Urol* 2001;  
685 165(Suppl):390.
- 686 28. Katz R, Salomon L, Hoznek A. Patient-reported sexual function following laparos-  
687 copic radical prostatectomy. *J Urol* 2002; 168:2078–2082.
- 688 29. Kavoussi LR. Laparoscopic radical prostatectomy: irrational exuberance?. *Urology*  
689 2001; 58:503–505.
- 690 30. Turk I, Serdar D, Winkelmann B, Schonberger B, Loening SA. Laparoscopic radical  
691 prostatectomy. *Eur Urol* 2001; 40:46–53.

**Laparoscopic Radical Prostatectomy**

**149**

692 **Author Queries**

- 693 AQ1: Au: Sentence okay?
- 694 AQ2: Au: On a stretch or on the stretch?
- 695 AQ3: Au: Is this correct?
- 696 AQ4: Au: Please see query 2.
- 697 AQ5: Is this the end of your quote?
- 698 AQ6: Au: Is this correct?
- 699 AQ7: Au: Please list all authors if known.
- 700 AQ8: Au: Is this correct?
- 701 AQ9: Au: Please list all author names if known.
- 702 AQ10: Au: Please list all author names if known.